



# Metatarsalgia: Diagnosis and Management

*Etiologies and differential diagnoses.*

## Objectives

- 1) To determine the etiology of plantar keratosis, diffuse callosities, callus under the first, second, and fifth metatarsal heads as well as to distinguish between diffuse and discrete plantar keratosis.
- 2) To describe the symptoms experienced by the patient with structural or mechanically induced metatarsalgia.
- 3) To be aware of the nature of associated digital deformities.
- 4) To review the biomechanics of metatarsalgia.
- 5) To be aware of common conditions resulting in pain in the forefoot which may be in the differential diagnosis for structural metatarsalgia.
- 6) To update the recent research on the etiology of structural metatarsalgia.
- 7) To update recent research on the effectiveness of metatarsal pads, insoles and custom foot orthoses in the treatment of metatarsalgia.
- 8) To be aware of the variety of prefabricated commercial paddings, insoles, and foot orthoses in the management of metatarsalgia.
- 9) To know the pedorthic management for patients with metatarsalgia.

Welcome to Podiatry Management's CME Instructional program. Our journal has been approved as a sponsor of Continuing Medical Education by the Council on Podiatric Medical Education.

You may enroll: 1) on a per issue basis (at \$15 per topic) or 2) per year, for the special introductory rate of \$99 (you save \$51). You may submit the answer sheet, along with the other information requested, via mail, fax, or phone. In the near future, you may be able to submit via the Internet.

If you correctly answer seventy (70%) of the questions correctly, you will receive a certificate attesting to your earned credits. You will also receive a record of any incorrectly answered questions. If you score less than 70%, you can retake the test at no additional cost. A list of states currently honoring CPME approved credits is listed on pg. 136. Other than those entities currently accepting CPME-approved credit, Podiatry Management cannot guarantee that these CME credits will be acceptable by any state licensing agency, hospital, managed care organization or other entity. PM will, however, use its best efforts to ensure the widest acceptance of this program possible.

**This instructional CME program is designed to supplement, NOT replace, existing CME seminars.** The goal of this program is to advance the knowledge of practicing podiatrists. We will endeavor to publish high quality manuscripts by noted authors and researchers. If you have any questions or comments about this program, you can write or call us at: **Podiatry Management, P.O. Box 490, East Islip, NY 11730, (631) 563-1604 or e-mail us at [bblock@prodigy.net](mailto:bblock@prodigy.net).**

Following this article, an answer sheet and full set of instructions are provided (p. 136).—**Editor**

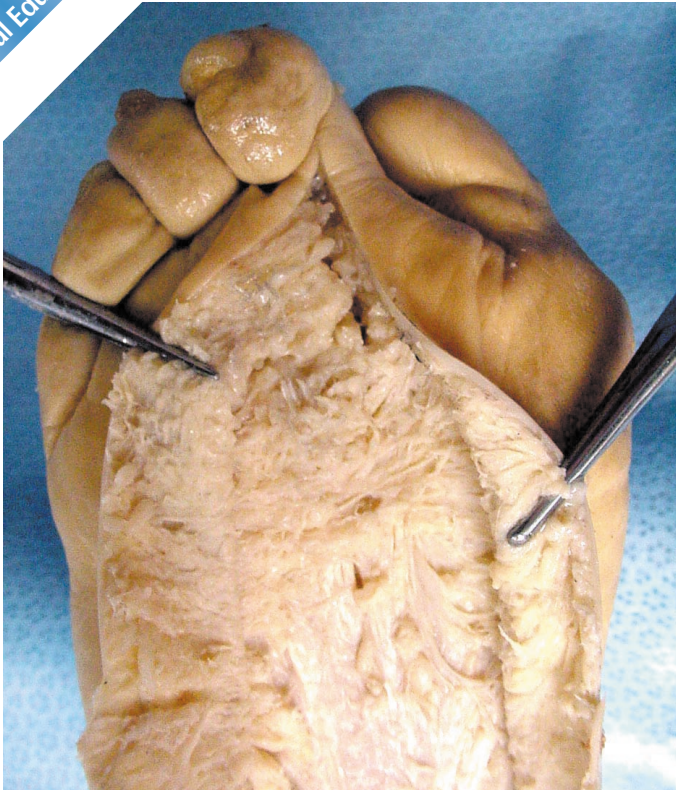By Ellen Sobel, D.P.M., Ph.D., C.PED. & Steven Levitz, D.P.M.

**P**ain under metatarsal heads with callus formation is an extremely common reason for seeking podiatric treatment and

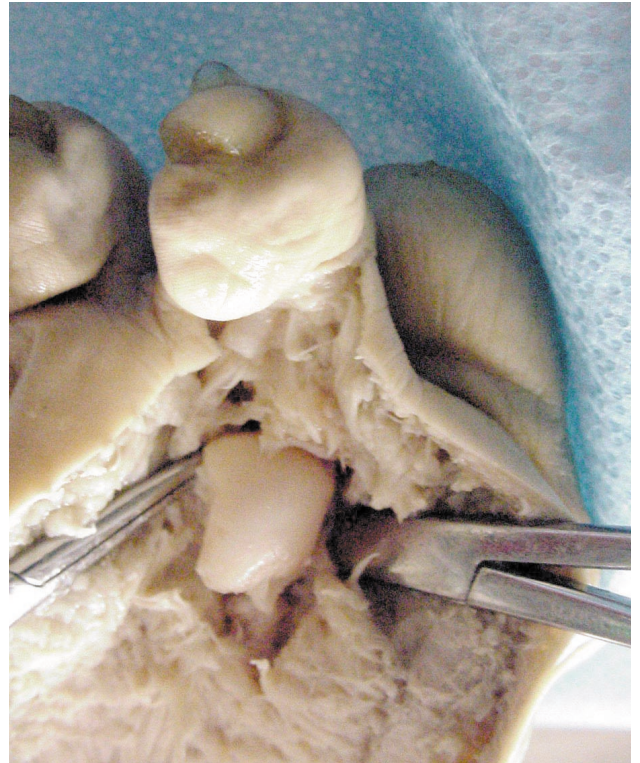forms the subject of this Continuing Podiatric Medical Education Article. The isolated complaint of metatarsalgia, with pain under the metatarsal head, has been called "primary" metatarsalgia,<sup>1,2</sup> pressure metatarsalgia,<sup>3</sup> or structural

metatarsalgia. Although there are numerous etiologies of metatarsalgia,<sup>4,5</sup> very few patients present with Freiberg's disease, let alone Tetralogy of Fallot as a cause of plantar forefoot pain. This CME article will

*Continued on page 79*



**FIGURE 1.** The normal plantar fat pad with fibrous septa.



**FIGURE 2A.** Second metatarsal head shows sharp plantar lateral condyle responsible for metatarsal callosity.



## Metatarsalgia...

focus on the most common structural causes of metatarsalgia, and provide several examples of frequently occurring differential diagnoses and the practical management of this common problem.

### Plantar Keratosis Callosities

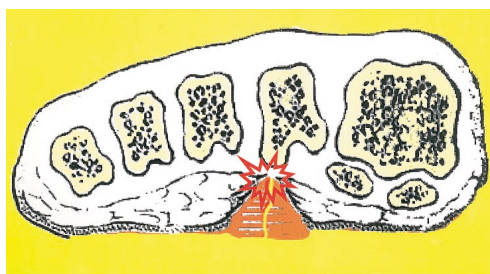
Plantar callus or tyloma is the most common cause of metatarsalgia. Pain limited to the head of the metatarsophalangeal articulation with callus formation beneath the metatarsal head is a sign of abnormal weight bearing pressure. The stress of the body weight results in an inflammation on the plantar surface of the head of the metatarsal bone as well as at the metatarsophalangeal articulation.<sup>6</sup> The plantar fat pad has been thought to atrophy with aging in some people and fails to provide adequate cushioning, producing generalized discomfort beneath the metatarsal heads (Figure 1).<sup>7</sup>

Hyperkeratosis or callus is a thickening of the skin caused by hyperplasia of the keratin layer, histologically similar to a corn.<sup>8,9,10,11</sup> It is found most frequently under one or more of the lesser metatarsal heads in the forefoot<sup>12,13</sup> especially under subcutaneous tissue thinned by continuous and excessive pressure.<sup>14</sup>

Metatarsal callosities are divided into large diffuse keratosis and well localized intractable plantar keratosis (IPK). DIFFUSE PLANTAR KERATOSES lack a discrete central core and are usually one to two centimeters in diameter.<sup>15</sup> They may be caused by a relatively long or plantar-flexed second metatarsal. The Morton's foot, consisting of a short first metatarsal, causes increased stress under the second metatarsal and subsequently a large, diffuse keratosis. In patients with significant hallux valgus deformity, the stress-absorbing function of the first metatarsal diminishes and a so-called transfer lesion develops under the second metatarsal.

### Intractable Plantar Keratosis (IPK)

The cause of the discrete IPK is an enlargement of the plantar lateral condyle of the metatarsal head (Figure 2A).<sup>10</sup> The condylar process on the fibular side is always the



**ENTRAPMENT OF CAPILIARY AND NERVE WITHIN THE IPK THE PLANTAR LATERAL CONDYLE IS PROTRUDING**

**FIGURE 2B. Entrapment of capillary and nerve within the IPK. The enlarged plantar lateral condyle is protruding.**

be thought of as a pinched nerve (Figure 2B).

Intractable plantar keratoses tend to occur under metatarsal heads two, three, and four, which may or may not be associated with hallux valgus. They are deep and painful, however, when an individual has multiple IPK's and they may not all hurt. Debridement reduces pressure to the ball of the foot 30%. After debridement moleskin padding can be placed over the callus for two to three days. Some patients will even bathe with the moleskin in place.

Normally, the dorsal angle of the metatarsophalangeal joint is about 160°. In a hammertoe deformity this angle may be reduced to 90°, at which angle the base of the proximal phalanx articulates with the dorsum of the head of the metatarsal. A hammer toe deformity causes the proximal phalanx to push down on the dorsal aspect of the metatarsal head, causing the metatarsophalangeal joint to

stretch and the glenoid plate to degenerate. This process can occur very quickly.

### Fifth Metatarsal Head Callus

Callus on the fibular side of the fifth metatarsal head occurs because the head of the fifth metatarsal is

*Continued on page 80*

**Plantar callus or tyloma is the most common cause of metatarsalgia.**

larger of the two. Pain produced by an IPK is caused by trapped nerves and capillaries (redipegs) resulting in neuritic pain. Therefore an IPK can

## Metatarsalgia...

the most prominent point on the outer border of the forefoot.<sup>16</sup>

*Case Presentation 1:* This 50 year old male maintenance worker had severe pain under the fifth metatarsal head for the past several years. Physical examination revealed a scar over the dorsum of the foot from removal of Morton's Neuroma (Figure 3A), with moderate callus formation under the fifth metatarsal head (Figure 3B). Numerous foot orthoses were of no help, despite the careful dispersion under the callus (Figure 3C). Careful palpation revealed a small fibroma on the slips of the lateral band of plantar fascia inserting into the fifth metatarsal (Figure 3B). One of

**The first metatarsal normally carries approximately twice as much weight as each lesser metatarsal.**

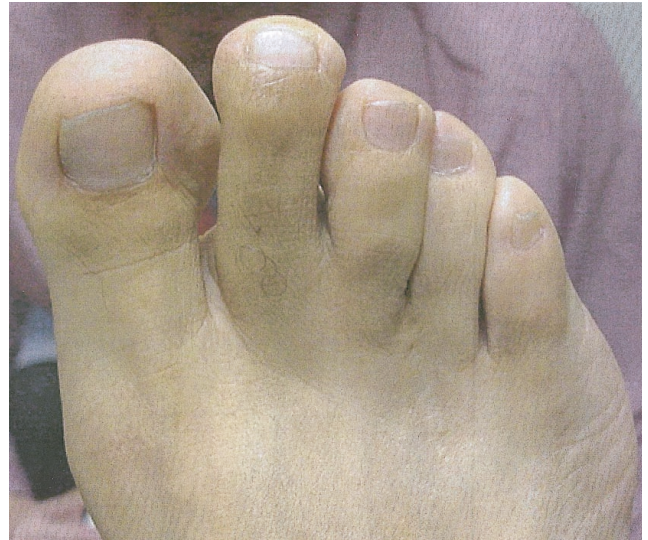the authors (SL) has removed three of these fibromas in patients who could not get relief with debridement and foot orthoses.

### First Metatarsal Head Callus

A special case is that of the callosity under the first metatarsal

head, which most commonly occurs under the tibial sesamoid. Hyperkeratotic lesions beneath the first metatarsal head are caused by an enlarged or malformed tibial sesamoid, or excessive plantar flexion of the first ray. The tibial sesamoid normally assumes more of the weight-bearing function transmitted to the head of the first metatarsal. During weightbearing the first metatarsal assumes a valgus torque and the lesser metatarsal heads assume a varus torque. This is another reason why the tibial sesamoid is more subject to excessive weightbearing under the first metatarsal head, and the lateral plantar condyles are more subject to weightbearing under the lesser metatarsal head.

Hallux valgus deformity frequently results in the first metatarsal head slipping off the sesamoid and the



**FIGURE 3A. Dorsum of the foot showing old surgical scar from removal of Morton's Neuroma.**

tibial sesamoid becomes a weight-bearing focus and causes a keratotic lesion. The keratotic lesion produced by the tibial sesamoid is a discrete, localized keratosis with a dense keratotic center. When this lesion is debrided, a punctate keratotic focus is identified.

### Biomechanics of the Metatarsal Heads

All of the metatarsals sustain the body's weight.<sup>17,18</sup> One-half of the body weight passes through each ankle minus the weight of the foot. Half of the force on the foot passes to the five metatarsal heads and the remaining half passes to the heel. If plantar weight bearing is divided into 12 units, 6 units will pass to the heel and 6 units will pass to the forefoot. Of the six units under the metatarsal head, each of the lesser metatarsals takes one unit and the first metatarsal head takes 2 units. Therefore the first metatarsal normally carries approximately twice as much weight as each lesser metatarsal.

Viladot<sup>18</sup> describes a first ray insufficiency syndrome in which the first metatarsal cannot bear its share of the weight. Conditions such as hallux valgus, short first metatarsal, metatarsus adductus, and proximal placement of the sesamoids result in reduced weightbearing for the first ray and place increased pressure under the lesser metatarsals. Flatfoot with resultant forefoot supinatus indirectly reduces the weightbearing under the first metatarsal head. Relaxation of the capsuloligamentous structures prevents the firm tight contact of the first metatarsal to the ground, resulting in an upward or dorsal tilt of the first metatarsal. Conversely, first ray overload syndrome, chiefly exemplified by hallux rigidus and sesamoiditis, places too much pressure on the first ray with possible clinical symptoms (callosity and pain) under the first metatarsal head.

Morton<sup>18</sup> proposed that the cause of metatarsalgia was a structural shortness of the first metatarsal which had to be compensated via lateral weight distribution. A functional shortness of the first metatarsal manifested with hypertrophy of the second metatarsal head and cortex, metatarsal-cuneiform split, and proximally dis-

*Continued on page 81*

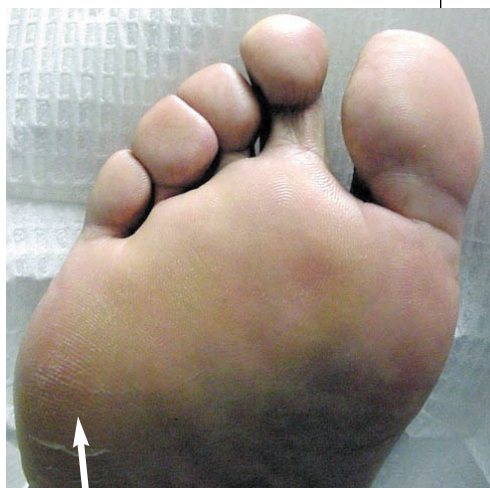## Metatarsalgia...

placed sesamoids. Observation of only one of these radiographic findings was considered evidence of a hypermobile first ray. The treatment for this malady was a Morton's articulating insole, which consisted of an insole with a 1/8 to 1/4 inch ele-

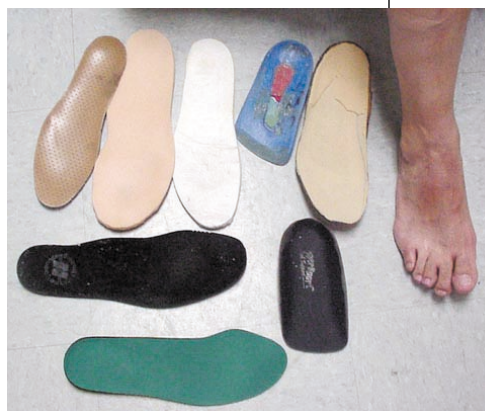vation, beneath the first metatarsal head, to redistribute weight.

It has been hypothesized that increased pressure under the metatarsal head results in fat pad atrophy which then causes pain under the metatarsal heads.<sup>9,19,20</sup> However, in a recent study to determine whether atrophy of the plantar fat

pad caused metatarsalgia, the thickness of the plantar fat pad under the second and third metatarsals was measured using ultrasound in 50 patients with metatarsalgia and varying degrees of fat pad atrophy. Atrophy of the plantar fat pad was not associated with increased severity or frequency of metatarsalgia.<sup>21</sup>



**FIGURE 3B.** Man with pain under fifth metatarsal head as shown by arrow.



**FIGURE 3C.** Numerous foot orthoses and adjustments were unsuccessful in alleviating pain because the pain was due to a small fibroma which could be palpated in the slips of the lateral band of plantar fascia.

## Subluxation of the 2nd Metatarsophalangeal Joint

A common cause of painful IPK's under the 2nd metatarsal head is subluxation and dislocation of the 2nd metatarsophalangeal joint with crossover deformity of the second toe.<sup>22</sup> The most important stabilizing structure of the MTP joint is the plantar plate, which is formed by the plantar aponeurosis and the plan-

*Continued on page 82*

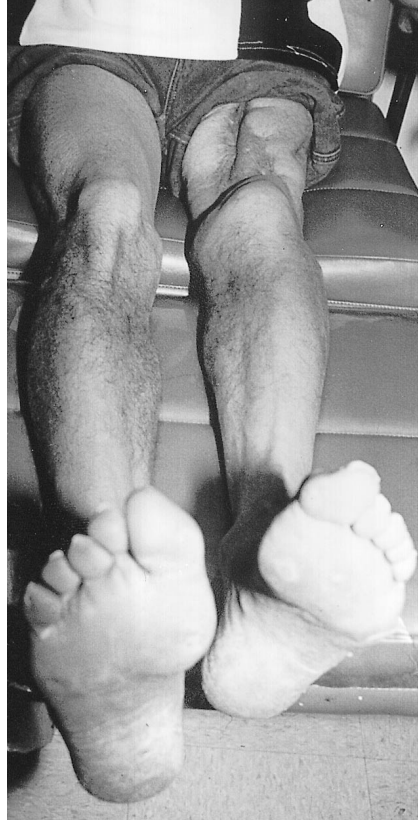

## Metatarsalgia...

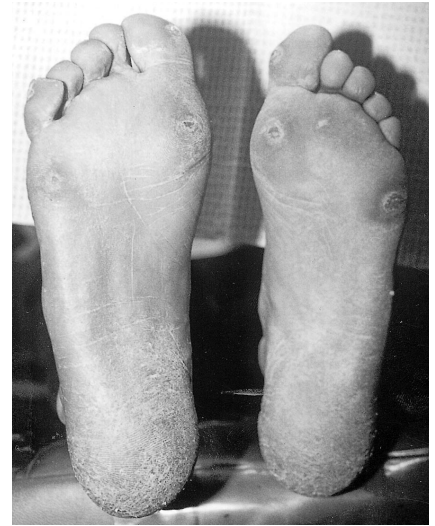
tar capsule.<sup>23</sup> Metatarsophalangeal joint instability can be produced by damage of the joint capsule, collateral ligaments, articular cartilage, or subchondral bone as a result of repetitive microtrauma (i.e., walking), or inflammatory, metabolic, and infectious diseases.<sup>24</sup> The use of high-heeled shoes may produce chronic hyperextension forces at the metatarsophalangeal joint that may cause stretching of the plantar aponeurosis and capsule with eventual instability of the metatarsophalangeal joint.<sup>23</sup> Chronic repetitive microtrauma disrupts the plantar plate and collateral ligaments. Synovitis from rheumatoid arthritis can also disrupt the plantar metatarsophalangeal joint ligaments and capsular structures.<sup>24</sup>

Once this joint stability is compromised, the intrinsic interosseous and lumbrical muscle, which flex the MPJ and extend the PIPJ and

*Continued on page 82*



**FIGURE 4A (left photo).** 39-year-old male with a 2.5 inch short left leg secondary to trauma when he was pushed off train tracks. He suffered severe muscle loss of the left lower extremity with weakness of all left extensor muscles and a fused right knee.



**FIGURE 4B.** 2.5 inch short left leg results in deep IPK's submetatarsals 1 and 5 on the left.

## Metatarsalgia...

DIPJ, are overcome by the stronger extrinsic muscles (EDL, EHL and FDL). This results in hyperextension of the MPJ and flexion of the PIPJ and DIPJ, producing hammertoe deformity.

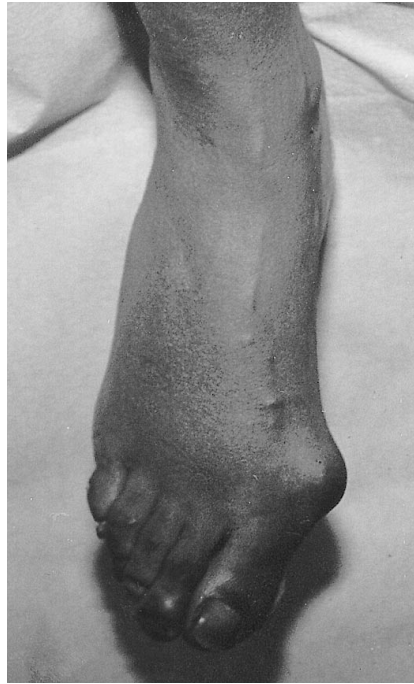
### Cavus Foot

Structural deformities such as cavus foot place increased pressure on the first and fifth metatarsal heads.<sup>25,26</sup> Contracted digits, atrophy of the fat pad, and rigidity tend to occur in the cavus foot type and exacerbate plantar pressures under the metatarsal heads. The plantar flexed metatarsals of the cavus foot also result in increased weightbearing pressure on the metatarsal heads.

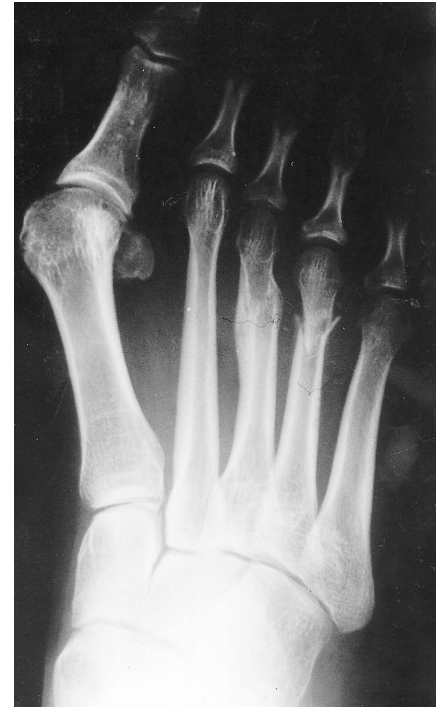### Limb Length Difference

After walking for prolonged periods of time with significant limb length discrepancy, the shorter leg will compensate with rigid ankle equines,

*Continued on page 84*

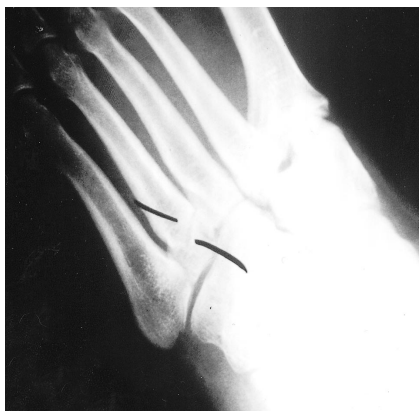

**FIGURE 5A. Clinical presentation of metatarsal fracture—pain and swelling over the dorsum of the right foot localized to the shaft of the second metatarsal.**



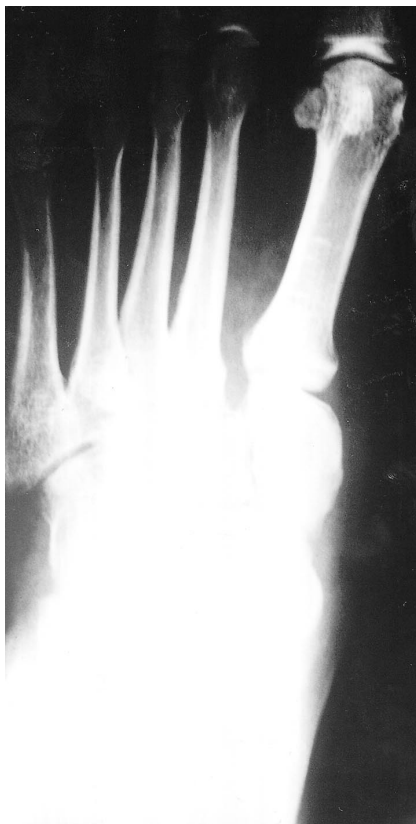**FIGURE 5B. Plain radiographs show healing of stress fractures of the 3rd and 4th metatarsal necks. The 4th metatarsal fracture is impacted.**

## Metatarsalgia...



**FIGURE 6A.** This man fell down some stairs and reported to the emergency room. The diagnosis was fracture of the base of the 4th metatarsal.

**FIGURE 6B (photo right).** However, DP radiograph shows abnormal space between the 1st and 2nd metatarsal and lateral malalignment of the second metatarsal over the intermediate cuneiform, which is evidence of LisFranc fracture dislocation, which was missed by the emergency room physician.



therefore increasing weight-bearing stress on the forefoot and the metatarsal heads. This results in callus formation (Figure 4A/B).

### Trauma

Metatarsal fractures are a common cause of metatarsalgia.<sup>27-30</sup> The most common stress fracture in the human body occurs in the second metatarsal neck, and is usually caused by excessive weight-bearing demand on this metatarsal bone (Figure 5A/B).<sup>27-30</sup> However, isolated fractures of the fourth metatarsal base are very uncommon and should indicate suspicion of LisFranc fracture dislocation.

*Case Presentation 2:* This 35 year-old dentist fell down several stairs and sprained his foot. Radiographs taken at a local emergency room revealed a fracture of the base of the fourth metatarsal (Figure 6A). The DP view of the same foot revealed a LisFranc fracture dislocation, which was missed at the ini-

*Continued on page 86*



## Metatarsalgia...

tial presentation (Figure 6B).

Metatarsal fractures may result in healing in such a way that the metatarsals are misshapen, more plantar flexed, creating additional pressure and callus formation in the forefoot.

*Case Presentation 3:* This 65 year-old female had painful callus under the third metatarsal head. She remembered previously injuring her foot about a year ago, but claimed that her foot had healed. Radiographs revealed a split third metatarsal head as a se-

quel of a probable third metatarsal fracture, which healed with a split metatarsal head (Figure 7).

The incidence of stress fractures

***Atrophy of the plantar fat pad was not associated with increased severity or frequency of metatarsalgia.***

to the metatarsals have been shown to be reduced in military recruits who wore soft custom foot orthoses.<sup>31,32</sup>

### Prior surgery

Patients who have had previous surgery on a metatarsal, especially removal of a metatarsal head, are likely to have painful callus on the adjacent metatarsal head.

*Case Presentation 4.* This 55 year-old female presents with chief complaint of painful callus located under the second metatarsal head (Figure 8A). Physical examination

*Continued on page 88*

**TABLE 1  
EFFECTIVENESS OF MECHANICAL TREATMENT OF  
METATARSALGIA-REVIEW OF THE LITERATURE**

STUDY	N	TREATMENT	MEASUREMENT	RESULTS
Holmes & Timmerman, 1990	10 healthy volunteers 5 females; 5 males	soft metatarsal pads (no other details)	Pedograph	Reduction in plantar pressure for woman 12% to 60% men 14% to 40%
Chang, Faraj, Harris, et al., 1994	10 healthy male subjects	Plastazote insoles (6.4 mm thick) rubber metatarsal pads-6 cm long 5.2 cm wide, .8 cm thick Distal margins 5 mm proximal to metatarsal heads. worn in P.W. Minor Extradept shoes	Interlink (Santa Barbara, CA) pressure sensors in portable in-shoe data acquisition system.	Significant increases in peak pressures, contact durations, pressure-time integrals at metatarsal shaft region with metatarsal pad use. Mild decrease in mean peak pressure under 1st & 2nd met head. Contact duration decreased at all met heads; pressure-time integrals decreased at mets 1-4.
Poon & Love, 1997	14 patients with metatarsalgia	Custom "metatarsal dome" foot orthoses	F-scan Visual analog pain scale	13% reduction in forefoot plantar pressure 71% reduction in pain as measured by visual analog scale.
Postema, Burm, Zande, et al 1998	42 patients with metatarsalgia 41 females 1 male	Custom molded insole & rockerbar added depth shoe (Patient casted full weightbearing) Metatarsal pad was 5 mm thick and 40mm long	EMED System	Rockerbar decreased peak pressure under forefoot 15% Custom molded insole decrease pressure under forefoot by 18%
Kelly & Winson, 1998	33 patients	Viscoped Insole (Bauerfeind, UK) Langer BlueLine orthosis (Langer, Deerpark, NY) for 8 weeks	Musgrave Footprint system. Visual analogue pain score.	Viscoped-6/18 patients rated much improved Langer Blue group 12/15 rated much improved Langer Blue Line group reduced forefoot plantar pressures significantly better than Viscoped insoles

## Metatarsalgia...

reveals a short third toe (Figure 8B). X-rays revealed surgical removal of the 3rd metatarsal head (Figure 8C).

### Neuromuscular Disease

Neuromuscular disease may result in pronounced muscle imbalance leading to particularly thickened painful metatarsal calluses (Figure 9A/B).<sup>33</sup>

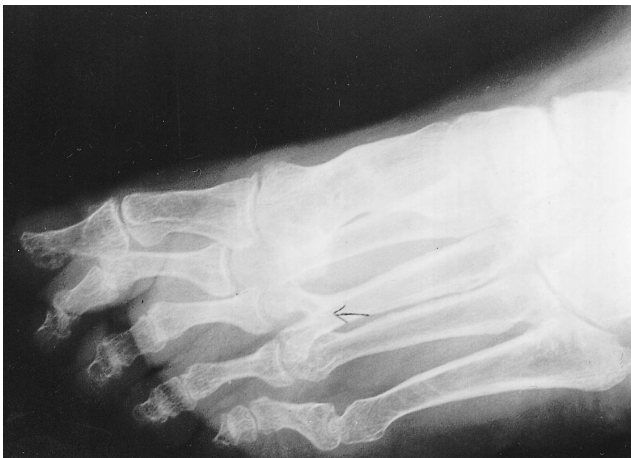### Brachymetatarsia

Brachymetatarsia disrupts the smooth metatarsal parabola resulting in uneven weightbearing with painful metatarsalgia.

*Case Presentation 5:* This 20 year-old female had a history of removal of a pituitary gland tumor several years previously, which caused her to require taking large doses of hormone therapy. This resulted in premature closure of the growth plates with brachymetatarsalgia (Figure 10).

### Clinical Presentation

When a patient complains of forefoot pain the first



**FIGURE 7.** Patient clinically had 3rd metatarsal callus. X-rays showed that a metatarsal fracture sustained about a year ago healed with split metatarsal heads. One of the metatarsal heads was directed plantarly, causing pain and callosity with ambulation.

thing is to observe whether a callus is present.<sup>34</sup> The subjective findings include pain under the metatarsals of a burning and cramping nature.<sup>6</sup> The objective findings include a plantar callus under the head of the metatarsal,

*The most common stress fracture in the human body occurs in the second metatarsal neck.*

often with individual or multiple contracted digits. There may be tenderness over the plantar surface of the metatarsals. There may also be a depression on the dorsum over the head of the metatarsal

bone. There may be decreased passive range of motion of the involved metatarsophalangeal joint.

### Associated Deformities

The contracted digital deformities are hammertoes, mallet toes, and claw toes. A hammertoe is a flexion contracture at the proximal interphalangeal joint. A corn frequently develops on the head of the proximal phalanx. Extrinsic pressure of the hallux against the second toe owing to restrictive shoe gear results in hammertoe deformity or subluxation or dislocation of the second metatarsal phalangeal (MTP) joint (crossover deformity).<sup>22</sup> A mallet toe is a flexion contracture of the distal interphalangeal joint making the distal aspect of the toe point toward the ground. A hard corn develops on the tip of the toe. A clawtoe is a flexion contracture at both the proximal and distal interphalangeal joints.<sup>35</sup> Clawed digits may be associated with neuromuscular disease.<sup>36</sup>

Hard corns (*heloma durum*) are an accumulation of several layers of epidermis over a bony prominence generally found on the lateral side of the fifth toe and on the dorsum of the toes as the skin rubs against the shoe.<sup>37</sup> They are the body's attempt to protect the skin over the bony prominence. Because there is no moisture in these locations, the corn remains hard. Soft corns (*heloma molle*) occur intertriginously most frequently in the fourth interspace in either the web space or the medial or lateral borders of the lesser digits. The soft corn retains the moisture of the interspace, which is responsible for its macerated soft texture.<sup>38</sup>

### Differential Diagnosis

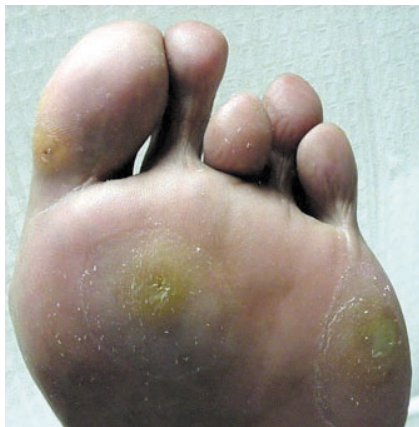A study of metatarsalgia in 98 patients revealed 23 distinct diagnoses.<sup>1</sup> Scranton<sup>1</sup> divided metatarsalgia into structural, systemic, and miscellaneous forefoot pain categories. Structural and postoperative etiologies were the most common causes of forefoot pain; however, rheumatoid arthritis, Morton's neuroma, and sesamoiditis were also relatively common. Although the great percentage of pain in the forefoot, especially under the metatarsal heads, is caused by callosities, the most common of these diagnoses will be considered.

*Continued on page 89*

## Metatarsalgia...

### Verruca Plantaris

It is important to distinguish verruca plantaris from plantar keratosis. The keratosis is mistakenly treated with anti-wart chemical applications until keratosis breaks down and ulcerates or leaves a permanent scar. A plantar wart is ten-

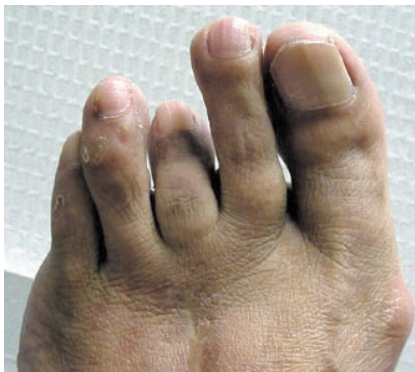

**FIGURE 8A.** Patient presents with chief complaint of painful 2nd metatarsal head callus.

der when it is squeezed from medial to lateral and bleeds easily when debrided. Plantar keratosis can be easily pared down fairly deep and will not bleed if debrided carefully.

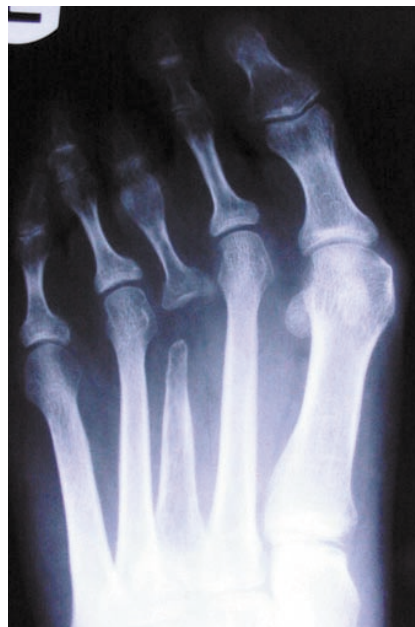### Morton's Neuroma

Morton's neuroma is a well-documented clinical entity which is most probably a mechanically-induced degenerative neuropathy that predilects for the third common digital nerve in middle-aged women.<sup>39-43</sup>



**FIGURE 8B.** Clinically there is a short 3rd toe.

The third common digital nerve is vulnerable to damage due to excessive motion between  
*Continued on page 90*

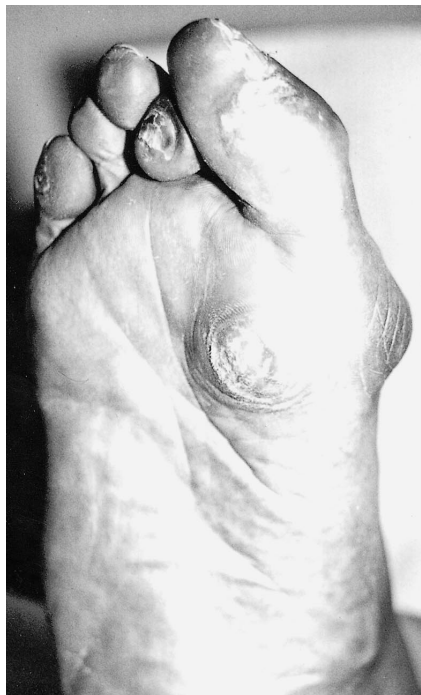


**FIGURE 8C.** X-rays reveal surgical removal of the 3rd metatarsal head.



## Metatarsalgia...

the third and fourth metatarsals, compression by the large overlying



transverse intermetatarsal ligament and weightbearing forces from high heeled shoes. Over long periods of time, nerve fiber degeneration, ex-

cessive intraneural and juxtaneural reparative fibrosis significantly enlarge the nerve, making it even more vulnerable to compression.

The metatarsal squeeze test is a clinical diagnostic test for this disorder.

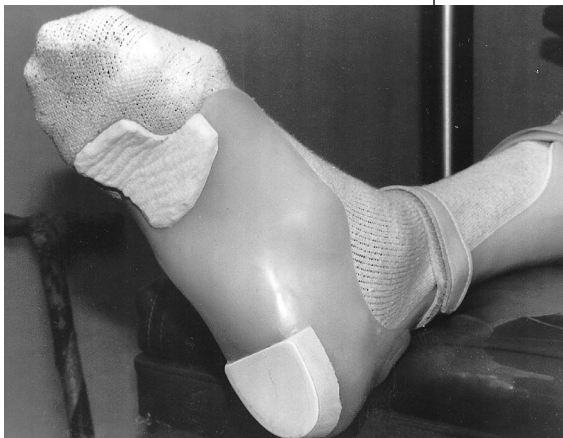### Systemic Arthritis

The metatarsophalangeal joints are the first areas of the foot to be involved in rheumatoid arthritis.<sup>44</sup> An x-ray of the foot with established and advanced rheumatoid arthritis shows characteristic subluxations at the metatarsophalangeal joints, but x-rays in the early diagnosis of rheumatoid arthritis are not helpful.

### Treatment

The treatment for plantar callosities be-

*Continued on page 92*



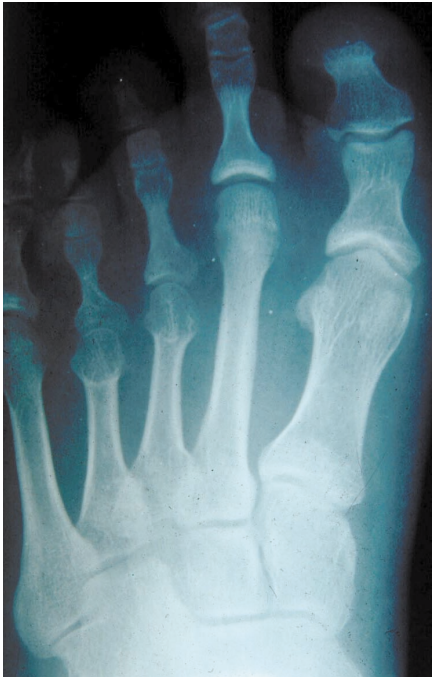**FIGURE 9B.** AFO padded with felt and a special foot plate with cut out for the first metatarsal was necessary to alleviate this patient's symptoms from the excess pressure of the callus.

**FIGURE 9A (photo left).** IPK under the first metatarsal head with contracted digits. Patient had a gunshot wound to the spine result in muscle imbalance, which led to the digital contractures.

## Metatarsalgia...

gins with debridement of diffuse callosities with enucleation of intractable plantar keratoses (IPK's). A surgical scalpel with a number ten surgical knife is used for debridement. A number fifteen surgical knife may be used for enucleation. Lubrication and hydration to maximize skin tone is essential. Callus debridement in one recent study found no significant difference in peak forefoot pressure before and after callus removal;<sup>45</sup> however, in another report, plantar forefoot pressures were reduced after debridement of calluses in diabetic patients.<sup>46</sup>

A hyperkeratolytic agent such as Carmol®-40% Urea



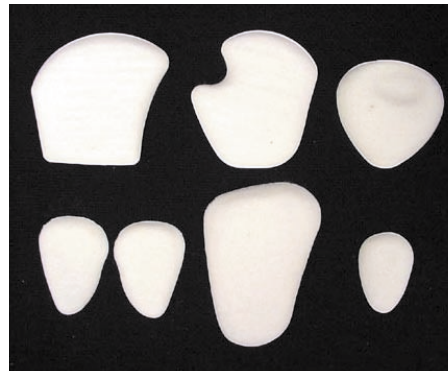**FIGURE 10.** This 20 year old female had a history of removal of a pituitary gland tumor several years previously which caused her to require taking large doses of hormone therapy, which resulted in premature closure of the growth plates with brachymetatarsalgia.

Cream (Doak Dermatologics, Fairfield, N.J.), or Amlactin® 12%-(12% ammonium lactate), may be helpful when hyperkeratosis is particularly thickened. These agents provide enzymatic debridement of calluses. Urea gently dissolves the intercellular matrix, which results in loosening the horny layer of the skin and shedding scaly skin at regular intervals, softening hyperkeratoses. Carmol®-40% Urea Cream is topically ap-

plied to affected skin twice per day and rubbing the cream into the skin until completely absorbed.

### Metatarsal Pads

Metatarsal pads are pear-shaped pads which are placed just proximal to the metatarsal heads to transfer

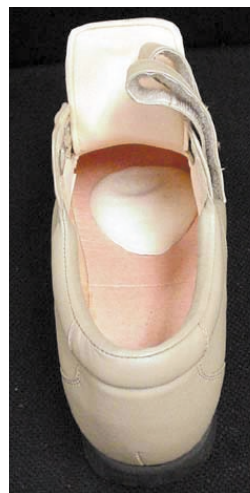

**FIGURE 11A.** Prefabricated wool felt metatarsal pads (Hapad, Inc., Bethel Park, PA) with adhesive backing.

and distribute body weight to necks and shafts of the metatarsals.<sup>47</sup> Metatarsal pads have been found to be effective in reducing pressure under the metatarsal heads. Soft metatarsal

metatarsal pads were effective in reducing pressure under the metatarsal heads in ten asymptomatic volunteers as measured by pedobarograph.<sup>48</sup> Subjects walked barefoot with the metatarsal pad taped to the foot. This study found that metatarsal pads were more effective in reducing plantar pressures in females than in males possibly because of previous use of high-heeled shoes or because of the smaller size of the female foot. The authors concluded that simple inexpensive metatarsal pads were an effective treatment for metatarsalgia, especially in female patients.

In a more recent but similar study, ten male asymptomatic volunteers walked in 6.4mm thick plastazote insoles with rubber metatarsal pads worn in P.W. Minor shoes.<sup>49</sup> Metatarsal pad use resulted in peak load increases in the midfoot region and mild decreases in the forefoot region under the 1st and 2nd metatarsal heads and slight increases laterally. Contact durations decreased at all metatarsal head locations. Therefore metatarsal pads seemed to redistribute pressure away from the metatarsal head more proximally into the metatarsal shaft. The authors concluded that insoles with metatarsal pads were an effective treatment for metatarsalgia.



Prefabricated wool felt metatarsal pads are available from Hapad, Inc. (Bethel Park, PA) (Figure 11A). These metatarsal pads have adhesive backing and are designed to be placed directly inside the shoe (Figure 11B). When a shoe is worn, the inside of the shoe can

*Continued on page 93*

**FIGURE 11B.** Prefabricated wool felt metatarsal pads (Hapad, Inc. Bethel Park, PA) with adhesive backing are designed to be placed directly inside the shoe and last the life of the shoe.

## Metatarsalgia...

be examined for pressure areas in the metatarsal region usually indicated by dark spots. The front of the pad is placed just proximal to the dark spot pressure area. While fitting the pad in the shoe, only a small portion of the adhesive on the back of the pad should be shown so that the pad can be placed in different spots until the patient feels comfortable in the shoe.

Special prefabricated metatarsal bandages are available from Apex Foot Health Industries (Hackensack, New Jersey), which slide easily on the foot and do not take up as much

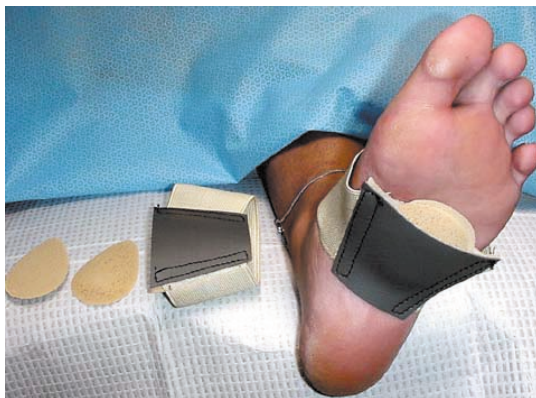*It is important to distinguish verruca plantaris from plantar keratosis.*

room as an insole or foot orthosis and can be worn in virtually any shoe with complete comfort (Figure 12).

### Insoles & Foot Orthoses

Insoles or accommodative foot orthoses assist in rebalancing to redistribute and disperse calluses and are made of soft materials such as plastazote, PPT, felt, foam rubber, sponge rubber, plastics, leather, Spenco®, and Sorbothane. Insoles and custom foot orthoses have been shown to reduce forefoot pressure and pain in patients with metatarsalgia (Figure 13A/B).

A number of studies have compared the effectiveness of various kinds of insoles on the relief of metatarsalgia and reduction of forefoot pressure. In a comparative study on the effectiveness of plastazote/PPT versus silicone insoles, plantar forefoot pressure was lowered in all patients. However, reduction in forefoot plantar pressure was 84% for those wearing the plastazote/PPT insoles for eight weeks versus 34% forefoot pressure reduction for those wearing silicone insoles for the same time period.<sup>3</sup>



**FIGURE 12. Metatarsal bandage (Apex Foot Health Industries, Hackensack, New Jersey).**

In another study, fourteen patients with metatarsalgia wore metatarsal dome orthoses with a follow-up of 15.5 weeks.<sup>50</sup> At the time of follow-up there was found to be a 13% decrease in mean forefoot plantar pressure and a 71% reduction in pain as measured by a visual analog scale, with 90% of patients wearing their orthoses most of the time. And in yet another similar study, custom moulded inserts resulted in reduc-

tion in plantar pressure of 7% to 9% under the metatarsal heads.<sup>51</sup>

In one study with several interesting conclusions it was found that custom molded insoles and a rockerbar were found to be effective in reducing central forefoot pressure in 42 patients with metatarsalgia.<sup>52</sup> It was determined that the custom molded insole reduced central forefoot pressure by 18% and the rocker bar contributed to reduc-

tion in forefoot pressure by approximately 15%. In this study, custom molded insoles reduced forefoot pressure better than prefabricated insoles. However, reduction in pain was not related to a reduction in pressure. Similarly, walking speed and body mass were found to be unrelated to plantar forefoot pressure in this study. The authors recommended prescribing the custom

*Continued on page 94*

**TABLE 2**  
**TYPES OF ROCKER BOTTOM SOLES**  
**(Adapted from Janesse D: Introduction to Pedorthics, Pedorthic Foot Wear Association, Columbia, Maryland, 1998)**

TYPE ROCKER	INDICATION
Mild Rocker Sole	Relieve metatarsal pressure Typically found on running shoes
Heel-to-toe Rocker Sole	Digital deformities such as hammer toes & claw toes Calcaneal ulcers Midfoot amputation
Toe-only rocker sole	Hallux rigidus
Severe angle rocker	For extreme relief of ulcerated metatarsal heads
Negative-heel rocker	Rigid calcaneus deformity Painful metatarsal heads
Double rocker sole	Midfoot charcot foot



## Metatarsalgia...

molded insole and rocker bottom shoe together.<sup>52</sup>

In patients with foot problems due to diabetes mellitus and

rheumatoid arthritis, foot orthoses have been effective in reducing fore-foot pressure and relieving metatarsal pain. In diabetic patients, custom foot inserts lowered metatarsal head pressure significant-

ly more than flat inserts.<sup>53</sup>

Twelve rheumatoid arthritis patients with second metatarsal head pain were treated with four different foot orthoses which included prefabricated, standard custom molded,



**FIGURE 13A.** A variety of insoles for relief of metatarsalgia. Top left 3/4 Comf-Orthotic® of wool felt with metatarsal lift and arch support (Hapad, Bethel Park, PA). Bottom left Soft Plastazote PPT combination insoles (Langer Biomechanics Group, DeerPark, New York). Top right Sorbolite shock absorbing Comfort Insole (IEM Medical Technologies, Inc, Ravenna, Ohio). Bottom right Hapad full length Comf-Orthotic® (Hapad, Inc., Bethel Park, PA).



**FIGURE 13B.** Variety of metatarsal pads and P.Q. Lady's dress shoe comfort inserts with special ball of the foot cushion. The insole is made of a special 3-layer material consisting of a top cover of smooth nylon, midlayer of SbR for shock absorption and a bottom layer of 1/8 inch pure PQ Visco elastic polymer for extra shock absorption (Riecken's Orthotic Laboratory, Evansville, Indiana).

custom molded with metatarsal dome, custom molded with metatarsal bar and a shoe-only control.<sup>54</sup> Results revealed that all orthoses significantly reduced pressure beneath the first and second metatarsal head compared to the shoe-only control as measured by the EMED Pedar system. However, the custom molded orthosis with a metatarsal dome

*Continued on page 95*

## Metatarsalgia...

was the most effective design for rheumatoid arthritis patients with painful second metatarsal heads.<sup>54</sup>

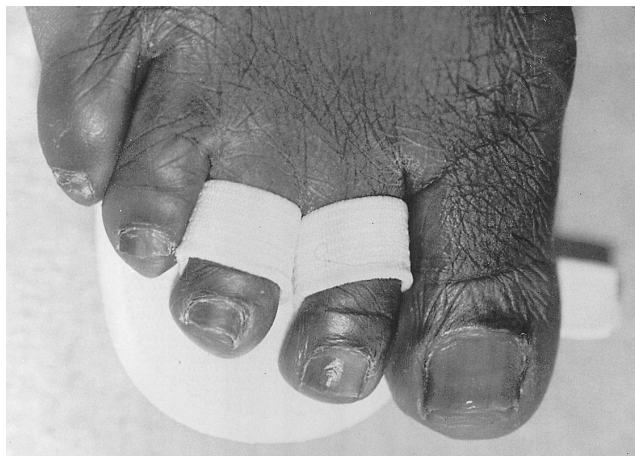### Footwear

Shoes should be well-padded, have rubber soles to cushion and absorb shock and have a relatively low heel. Depth inlay orthopedic shoes have a large upper to accommodate hammer digits and are large enough to fit an insole. A shoe with a rocker bottom sole has the anterior half of the sole curved upward toward the end of the shoe with the apex of the curve just proximal to the metatarsal heads allowing for a smooth transmission from heel to toe during stance phase of gait. Shoes with rocker-bottom soles have been shown to reduce pressure under the metatarsal heads and are a frequently recommended external

**Metatarsal pads have been found to be effective in reducing pressure under the metatarsal heads.**

shoe modification for metatarsalgia.<sup>55,56</sup> Of the six types of rocker-bottom soles (Table 2), the mild rocker sole is the most commonly used and is effective in relieving metatarsal pressure.<sup>57</sup> Since the mild rocker is frequently found on running shoes, the heavy cushioning of the better men's running shoes in conjunction with the rocker sole makes this an excellent choice for patients with metatarsalgia.

A metatarsal bar, not to be confused with a rockerbar, is another external shoe modification which works as a fulcrum to reduce metatarsophalangeal extension forces creating a negative heel effect.<sup>57</sup> The bars are made from leather or crepe and should be no



**FIGURE 14. Budin splint to stretch toe and pad metatarsal heads.**

thicker than 3/8 of an inch. The metatarsal bar should be located proximal to the metatarsal heads of the foot.

Treatment of associated hammer digits consists of observation if not symptomatic. Shoe wear with higher toe box, low heel, depth inlay shoe is recommended. Debridement of the associated corn and plantar callosity is always helpful. Silicone toe sleeve may be placed directly on the affected hammered digit. A Budin splint (figure 14), or silicone gel metatarsal cushion (Apex Foot Health Industries, Hackensack, NJ (Figure 15)) may be applied to extend a flexible hammer digit. Surgical referral is recommended if the problem is extremely painful and does not respond to conservative treatment.

For high-heeled dress shoes thin lightweight prefabricated foot orthoses with a spring arch design are available from the Eneslow Foot Comfort Center (New York, New York) (Figure 16). ■

### References

- 1 Scranton PE: Metatarsalgia: Diagnosis and Treatment. *J Bone Joint Surg.* 62A: 723-32, 1980.
- 2 Scranton PE: Metatarsalgia: A clinical review of diagnosis and management. *Foot Ankle* 1: 229, 1981.
- 3 Kelly A, Winson I:

Use of ready-made insoles in the treatment of lesser metatarsalgia: A prospective randomized controlled trial. *Foot Ankle* 19: 217-220, 1998.

<sup>4</sup> Albert SF, Jahnigen DW: Treating common foot disorders in older patients. *Geriatrics* 38: 42-55, 1983, June.

<sup>5</sup> Pack LG, Julien PH: Differential diagnosis of lesser metatarsalgia. *Clin Podiatr Med Surg* 7(4): 573-7, 1990.

<sup>6</sup> Hauser EDW: Diseases of the foot. W.B. Saunders Company, Philadelphia, 1941. pp. 311-314.

<sup>7</sup> Mann RA: Metatarsalgia Common causes and conservative treatment. *Postgraduate Medicine* 75:150-67, 1984.

<sup>8</sup> Helfand A: Nail and hyperkeratotic problems in the elderly foot. *AFP:* 39(2) 101-110, 1989.

<sup>9</sup> Helfand AE Lesser metatarsalgia in the geriatric patient. *Clin Podiatr Med. Surg.* 7(4): 743-749, 1990.

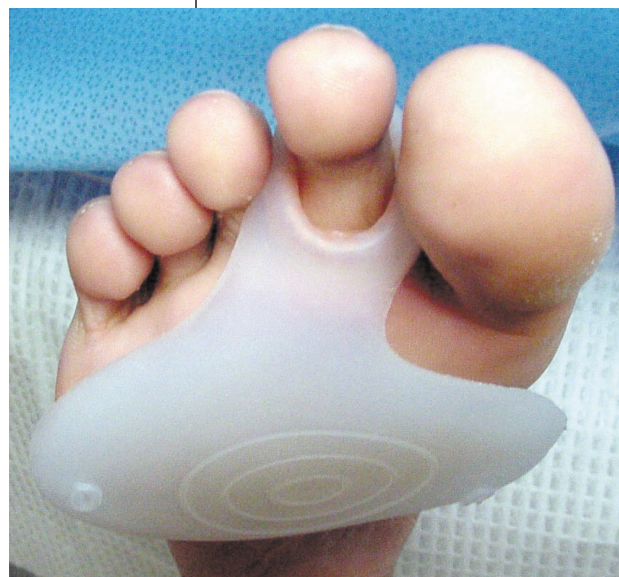<sup>10</sup> Mann RA, DuVries HL: Intractable plantar keratosis. *Orthop Clin North Am* 41: 67, 1973.

<sup>11</sup> Mann RA: Keratotic disorders of the plantar skin. In *Surgery of the Foot and Ankle*, ed by RA Mann, St. Louis, CV Mosby Company, 1986. Chapter 7. pp. 180-198.

<sup>12</sup> Calliet R: *Foot and Ankle Pain*. F.A. Davis Company, Philadelphia, 1982, edition 2.

<sup>13</sup> Friedman SL: "Palliative Care," In JM Robbins: *Primary Podiatric Medicine*. W.B. Saunders Company, Philadelphia, 1994, Chapter 13, 167-82.

<sup>14</sup> Klenerman L, Nissen KI, Baker H: *The Foot and Its Disorders*, Blackwell Scientific  
*Continued on page 96*



**FIGURE 15. Anti-Shox® Gel Metatarsal Cushion (Apex Foot Health Industries, Hackensack, New Jersey.)**



## Metatarsalgia...

Publications, 1976, pp. 131-63.

<sup>15</sup> Silfverskiold JP: Common foot problems. *Postgrad* 89(5) 183-8, 1991.

<sup>16</sup> DuVries HL: *Surgery of the Foot*. C.V. Mosby Company, St. Louis, 1959.

<sup>17</sup> Morton DJ: *The Human Foot*, New York, Columbia University Press, 1948.

<sup>18</sup> Viladot A: Metatarsalgia due to biomechanical alterations of the forefoot. *Orthop Clin NA* 4: 165-178, 1973.

<sup>19</sup> Chairman EL: Restoration of the plantar fat pad with autoliptransplantation. *J Foot Ankle Surg*. 33: 373-379, 1994.

<sup>20</sup> Hlavac H: The plantar fat pad and some related problems. *J Am. Podiatr. Assoc.* 60: 151-155, 1970.

<sup>21</sup> Waldecker U: Plantar fat pad atrophy: A cause of metatarsalgia? *J Foot Ankle Surg* 40(1): 21-27, 2001.

<sup>22</sup> Weinfeld SB: Evaluation and management of crossover second toe deformity. *Foot Ankle Clin* 3(2) 215-228, 1998.

<sup>23</sup> Coughlin MJ: Subluxation and dislo-

**Shoes with  
rocker-bottom soles  
have been shown  
to reduce pressure  
under the  
metatarsal heads.**

cation of the second metatarsophalangeal joint. *Orthop Clin North Am* 29: 535-551, 1989.

<sup>24</sup> Mann RA, Mizel MA: Monoarticular nontraumatic synovitis of the metatarsophalangeal joint: A new diagnosis. *Foot Ankle* 6: 18-21, 1985.

<sup>25</sup> Jimenez AL, Martin DE, Phillips AJ: Lesser metatarsalgia evaluation and treatment. *Clin Podiatr Med Surg* 7(4): 597-618, 1990.

<sup>26</sup> Subotnick SI: The Cavus Foot *Phys Sport Med* 8(7): 53-5, 1980.

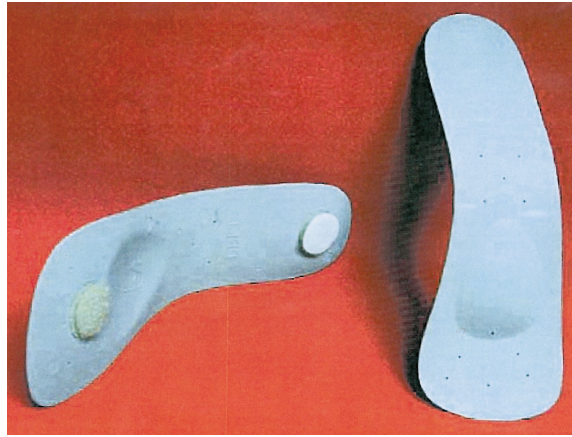
<sup>27</sup> Childers RL, Meyers DH, Turner PR: Lesser metatarsal stress fractures: A study of 37 cases. *Clin Podiatr Med Surg* 7(4): 633-44, 1990.

<sup>28</sup> Kaye Ra: Insufficiency stress fracture of the foot and ankle in postmenopausal women. *Foot Ankle Int* 19: 221-224, 1998.

<sup>29</sup> Shereff MJ: Complex fractures of the metatarsals Review Article: *Foot and Ankle Series. Orthopedics* 13: 875-82, 1990.

<sup>30</sup> Spector FC, Karlin JM, Scurran BL, Silvani SL: Lesser metatarsal fractures Incidence, management, and review. *J Am Podiatr Med Assoc* 74(6): 259-64, 1984.

<sup>31</sup> Finestone A, Giladi M, Elad H, et al:



**FIGURE 16. Walking Balance Orthotics especially designed to wear with high heeled shoes (Eneslow Foot Comfort Center, New York, NY.)**

Prevention of stress fractures using custom biomechanical shoe orthoses. *Clin Orthop Rel Res*. 360: 182-190, 1999.

<sup>32</sup> Milgrom C, Giladi M, Kashtan H, et al: A prospective study of the effect of a shock-absorbing orthotic device on the incidence of stress fractures in military recruits. *Foot Ankle* 6: 101-104, 1985.

<sup>33</sup> Sobel E, Giorgini R: Problems and management of the rearfoot in neuromuscular disease. A report of ten cases. *J Amer Podiatr Med Assoc* 89 (1): 24-38, 1999.

<sup>34</sup> Coughlin MJ; Common causes of pain in the forefoot in adults. Review article. *J Bone Joint Surg* 82B: 781-9, 2000.

<sup>35</sup> Sands AK, Byck DC: Idiopathic clawed toes. *Foot Ankle Clin* 3(2): 245-58, 1998.

<sup>36</sup> Teasdall RD: Neuropathic clawed toes. *Foot Ankle Clin* 3(2): 229-43, 1998.

<sup>37</sup> Astion DJ: The fifth toe hard corn. *Foot Ankle Clin* 3(2): 305-11, 1998.

<sup>38</sup> Donley BG, Gates NT: Interdigital corns. *Foot Ankle Clin* 3(2): 293-303, 1998.

<sup>39</sup> Oliver TB, Beggs I: Ultrasound in the assessment of metatarsalgia: A Surgical and Histological Correlation. *Clin Radiol* 53: 287-9, 1998.

<sup>40</sup> Quirk R: Morton's neuroma. *Australian Fam Phys* 16(8): 1117-20, 1987.

<sup>41</sup> Williams JW, Meaney J, Whitehouse GH, et al: MRI in the Investigation of Morton's Neuroma: Which Sequences? *Clin Radiol* 52: 46-9, 1997.

<sup>42</sup> Younger ASE, Claridge RJ: The role of diagnostic block in the management of Morton's neuroma. *Can J Surg* 41(2): 127-30, 1998.

<sup>43</sup> Wu KK: Morton neuroma and metatarsalgia. *Curr Opin Rheumatol* 12(2): 131-42, 2000. (Published posthumously, Dr. Wu died November 25, 1999.)

<sup>44</sup> Sobel E, Caselli MA, McHale K: Pedal Manifestations of Musculoskeletal Disease. *Clin Podiatr Med Surg*. 15: 435-480, 1998.

<sup>45</sup> Potter J, Potter MJ: Effect of callus removal on peak plantar pressures. *The Foot* 10: 23-26, 2000.

<sup>46</sup> Young MJ, Cavanagh PR, Johnson TG, Murray MM, Boulton AJM: The effect of callus removal on plantar foot pressures in diabetic patients. *Diabetic Med* 9: 55-7, 1992.

<sup>47</sup> Milgram JE: Office measures for relief of the painful foot. *J Bone Joint Surg* 46A 1095-1116, 1964.

<sup>48</sup> Holmes GB; Timmerman L: A quantitative assessment of the effect of metatarsal pads on plantar pressures. *Foot Ankle* 11: 141-145, 1990.

<sup>49</sup> Chang A, Abu-Faraj ZU, Harris GF, Nery J, Shereff MJ: Multistep measurement

of plantar pressure alterations using metatarsal pads. *Foot Ankle Intern* 15: 654-660, 1994.

<sup>50</sup> Poon C, Love B: Efficacy of foot orthotics for metatarsalgia. *The Foot*, 202-204, 1997.

<sup>51</sup> Bennett P, Miskewitch V, Duplock L: Analysis of the effects of custom moulded foot orthotics. *Gait Posture* 3, 183, 1994.

<sup>52</sup> Postema K, Burm PET, Zande ME, Limbeek JV: Primary metatarsalgia: Influence of a custom moulded insole and a rockerbar on plantar pressure. *Pros Orthot intern* 22: 35-44, 1998.

<sup>53</sup> Lord M, Hosein R: Pressure redistribution by molded inserts in diabetic footwear A pilot study. *J Rehab Res Dev* 31: 214-221, 1994.

<sup>54</sup> Hodge MC, Bach TM, Carter GM: Orthotic management of plantar pressure and pain in rheumatoid arthritis. *Clin Biomech* 14(8): 567-575, 1999.

<sup>55</sup> Nawoczenski DA, Birke JA, Coleman WC: Effect of rocker sole design on plantar forefoot pressures. *JAPMA* 78: 455-60, 1988.

<sup>56</sup> Schaff PS, Cavanagh PR: Shoes for the insensitive foot: The effect of a "rocker bottom" shoe modification on plantar pressure distribution. *Foot Ankle* 11: 129-140, 1990.

<sup>57</sup> Janisse D: Introduction to Pedorthics. *Pedorthic Footwear Association*, Columbia, Maryland, 1998.

*CME Exam on page 100*



**Drs. Levitz and Sobel are professors in the Department of Orthopedics, NYCPM.**



# EXAMINATION

See instructions and answer sheet on pages 136-138.

- 1) What is the most common cause of forefoot pain?
  - A) Morton's neuroma
  - B) Rheumatoid arthritis
  - C) Osteoarthritis
  - D) Callus
- 2) The nature of the pain in intractable plantar keratosis can be characterized as:
  - A) Vascular
  - B) Psychological
  - C) Neuritic
  - D) Endocrinological
- 3) What is the most common cause of intractable plantar keratosis?
  - A) Enlargement of the plantar medial condyle of the metatarsal head
  - B) Enlargement of the plantar lateral condyle of the metatarsal head
  - C) Clawtoe deformity of the corresponding digit
  - D) Plantar flexion of the metatarsal head
- 4) What is the most common etiology of a callus under the first metatarsal head?
  - A) Enlargement of the tibial sesamoid
  - B) Enlargement of the fibular sesamoid
  - C) Cavus foot
  - D) Forefoot valgus deformity
- 5) Which of the following results in first ray overload syndrome?
  - A) Relaxation of the capsuloligamentous structures of the first metatarsal
  - B) Hallux valgus
  - C) Sesamoiditis
  - D) Flatfoot
- 6) What is the torque of the metatarsals?
  - A) Neutral torque
  - B) Valgus torque of the first metatarsal and varus torque of the lesser metatarsals.
  - C) Varus torque of all five metatarsals
  - D) Valgus torque of the lesser metatarsals and neutral torque of the first metatarsal
- 7) The findings of recent research on metatarsal pads and foot orthoses show that:
  - A) They have been found to reduce pressure, but only in asymptomatic subjects.
  - B) They have been shown to reduce pressure in asymptomatic subjects and patients with metatarsalgia.
  - C) They have been shown to reduce pressure in

Continued on page 100

Continuing  
Medical Education

## EARN CME CREDITS FROM PODIATRY MANAGEMENT

**Now you can earn CME credits by carefully reading articles and answering questions.**

You have two methods to enroll: 1) on a per issue basis (at \$15 per topic) or 2) per year for the special introductory rate of \$99 (you save \$51). You may submit the answer sheet, along with your check (payable to *Podiatry Management*) and your state license number(s).

If you correctly answer seventy percent (70%) of the questions correctly, you will receive a certificate attesting to your earned credits. This program is approved by the Council on Podiatric Medical Education (CPME). *PM's* CME program is valid in all states except Kentucky, Pennsylvania, and Texas. *Podiatry Management* cannot guarantee that these CME credits will be acceptable by any state licensing agency, hospital, managed care organization, or other entity. *PM* will, however, use its best efforts to ensure the widest acceptance of this program possible.

**This instructional CME program is designed to supplement, NOT replace, existing CME seminars.** The goal of this program is to advance the knowledge of practicing podiatrists. We will endeavor to publish high-quality manuscripts by noted authors and researchers. If you have any questions or comments about this program, you can write us at: *Podiatry Management*, P.O. Box 490, E. Islip, NY 11730, or e-mail us at [bblock@prodigy.net](mailto:bblock@prodigy.net) or call us at 1-631-563-1604.

Simply go to page 77, read the article by Drs. Sobel and Levitz, and/or go to page 123 and read the article by Dr. Rehm, then answer the 20 multiple choice questions that correspond to each article. You then have the choice to mail, fax, or call in your answers.

Circle #25

# EXAMINATION

(cont'd)

asymptomatic subjects and symptomatic patients as well as reduce pain in symptomatic patients  
D) While they are effective clinically, they have not been demonstrated to reduce pressure in asymptomatic individuals or patients with metatarsalgia

8) Recent research on patients with plantar metatarsal calluses have shown that when calluses are debrided:

- A) Plantar pressure is reduced
- B) Plantar pressure is not reduced
- C) Plantar pressure may or may not be reduced
- D) Pain is not reduced

9) What has recent research found pertaining to the relationship between plantar fat pad atrophy and metatarsalgia?

- A) Atrophy of the plantar fat pad has been found to be one etiology of metatarsalgia
- B) Atrophy of the plantar fat pad has been found to be associated with metatarsalgia, but does not in a causal manner
- C) Plantar fat pad atrophy is associated with increased pressure under the plantar fat pad, but does not cause pain
- D) There is no relationship between atrophy of the plantar fat pad and metatarsalgia

10) What is the main stabilizing structure of the MTP joint?

- A) Plantar plate
- B) Flexor digitorum longus
- C) The metatarsal lateral collateral ligament
- D) The metatarsal phalangeal plantar ligament

11) In Scranton's study of metatarsalgia, what were the most common diagnoses?

- A) Rheumatoid arthritis and Morton's neuroma

- B) Sesamoiditis and trauma
- C) Metatarsophalangeal subluxation
- D) Structural and postoperative

12) Which is NOT TRUE pertaining to metatarsal pads?

- A) Metatarsal pads can be placed directly in the shoe.
- B) Metatarsal pads increase pressure under the metatarsal necks.
- C) Metatarsal pads are placed directly under the metatarsal heads.
- D) Metatarsal pads can be made out of wool felt.

13) Summarizing the literature on insoles/foot orthoses used to treat metatarsalgia, which of the following insoles would have the best pain and pressure-reducing features?

- A) Prefabricated, soft and laminated
- B) Prefabricated, soft, laminated and containing metatarsal pad
- C) Custom molded, semirigid foot orthosis
- D) Custom molded, soft, with metatarsal pad

14) Which shoe feature or modification would be LEAST helpful for a patient with metatarsalgia?

- A) Rocker bar
- B) High toe box
- C) Rubber sole
- D) SACH heel

15) Which type of insert/foot orthosis has been most effective in preventing stress fractures?

- A) Semi-rigid custom foot orthoses
- B) Soft accommodative foot orthoses
- C) Prefabricated laminated insoles
- D) None of these

16) All of the following may result in excess plantar metatarsal

callus formation EXCEPT:

- A) Short leg with equinus contractures
- B) Removal of metatarsal head
- C) Calcaneus foot type
- D) Fracture of a metatarsal

17) Plantar metatarsal callus is a thickening of the skin caused by hyperplasia of the keratin layer, histologically similar to a dorsal digital heloma durum.

- A) True
- B) False

18) Why must fractures of the 4th metatarsal be observed very carefully?

- A) Because they are difficult to heal.
- B) Because they are easily missed and more common than once thought.
- C) Because they are associated with osteoporosis in menopausal females.
- D) Because they are associated with LisFranc fracture dislocation.

19) The best use of prefabricated wool felt metatarsal pads available from Hapad, Inc. (Bethel Park, PA) is to:

- A) Place them directly on the skin
- B) Place them on an insole
- C) Place them directly in the shoe
- D) Place them on a custom foot orthosis

20) What type of rocker sole is most frequently found on running shoes?

- A) There usually is no rocker sole on running shoes.
- B) Double rocker
- C) Sharp angle rocker
- D) Mild rocker

**SEE INSTRUCTIONS  
AND ANSWER SHEET  
ON PAGES 136-138.**