



# The Syndesmosis Procedure: An Alternative for Hallux Valgus Surgery

A biological bridge to restoration of form and function is a challenge to the “gold standard.”

BY DIETER J. FELLNER, DPM

**Editor’s Note:** Dr. Fellner recently returned from a visit to Hong Kong in which he had an opportunity to interview and observe Dr. Daniel Wu (Figure 1) about the syndesmosis procedure.

With over 30 years of experience, orthopedist Dr. Daniel Yang Wu’s work is distinguished by one simple fact. He holds the firm conviction that ‘breaking bones’ to fix bunions is wrong. He has never once used an osteotomy to correct hallux valgus. His fourth peer-reviewed article on the subject is about to be published.<sup>8</sup> In spite of his success, the respect he has earned from his patients, spanning over several decades, publications, and numerous interviews to newspaper, magazines, and TV, the syndesmosis procedure remains largely ignored by the international foot surgery community. Shaping and changing the status quo is not for the fainthearted.

Dr. Wu has performed over 1,400 syndesmosis procedures, and is today the world’s leading authority (Figure

2). The origin of the syndesmosis procedure can be traced to the 1960s with the work of the Italian orthopedists Botteri and Castellana (Figure 3).<sup>3</sup> In the 1970s, Florence orthopedists Pagella and Pierleoni described a case series of 145 osteodesis procedures.<sup>6</sup> In 1999, there is a further article by the British orthopedist Irwin Cape, reporting on 75 intermetatarsal osteodeses, entitled “A Fresh Approach To Hallux Valgus.”<sup>2</sup> The lit-

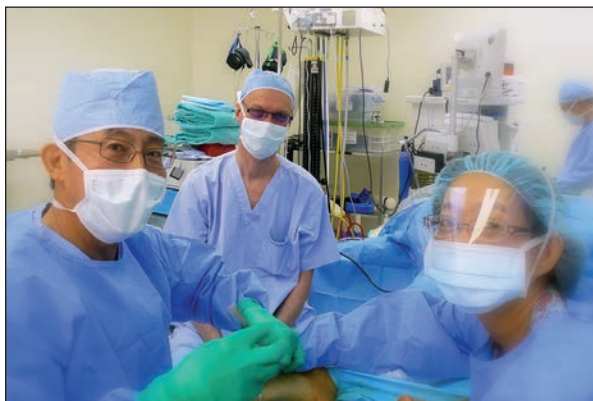

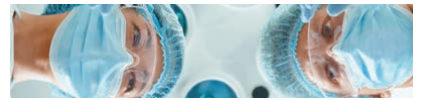
Figure 1: In the OR Dr. Wu (left), Dr. Fellner (center)

erature again remains dormant until the publication by Chinese orthopedist Dr. Wu, in 2006, first published in the Hong Kong journal *Orthopedic Surgery*.<sup>5</sup> Later, he produced three additional papers in well-respected peer reviewed journals.<sup>4,7,8</sup> Although separated by time and distance, all of

*Continued on page 118*

## New Concepts and Studies

**“New Concepts” is a forum for the presentation of (1) new technologies and products which have been the subject of clinical study, and (2) new studies involving existing products. Readers should be aware that Podiatry Management does not specifically endorse any of the technologies, concepts, or products being discussed.**



## Syndesmosis Procedure (from page 117)

the authors seem to concur that the procedure has merit.

Dr. Wu insists that the fact that there are so many different surgical approaches strikes at the heart of the problem. Why do we need so many different ways to correct the same foot deformity? There is no other example in the orthopedic world, no other single condition that is managed surgically with such a variety of operative approaches. For Dr. Wu, who also is a sports medicine specialist with additional specialist skills in shoulder arthroscopy, “less is more.”

There is no true ‘bone deformity’ that exists in the hallux valgus patient. He goes on to explain that the great toe and the first metatarsal are pushed out and away from their natural anatomical position. There is no comparable orthopedic management that involves cutting an anatomically normal bone (osteotomy) in an attempt to correct a positional displacement. He asks, “Can you see a true bone deformity?”

When Dr. Wu was asked if he believes that wearing high heels causes

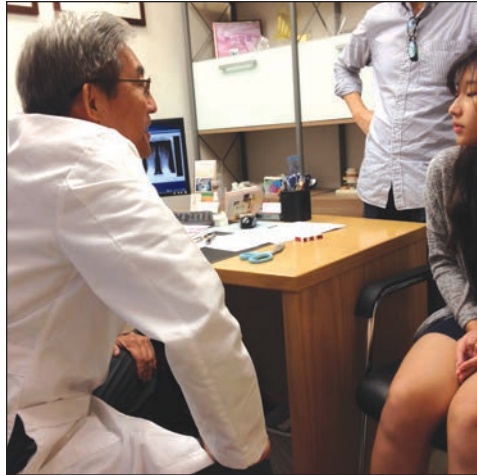


Figure 2: Dr. Wu, Office

hallux valgus, he directs you to his own report, which concluded that the great majority of his patient population do not wear high-heeled shoes.<sup>9</sup> He believes instead that the explanation is to be found from the effect of estrogen, coupled with genetics. This combination can exploit the inherent

construct to maintain correction.

The syndesmosis will also utilize a cerclage technique, using absorbable suture material, but only for the initial correction. The correction is permanently maintained with the induction of new tissue to form a biological bridge between the first and second metatarsals. This, he explains to a new patient, might be thought of as forming a new ligament to connect the segments. And that is the key element of the syndesmosis. Together with careful protection of the foot after surgery, this can provide a superior, more reliable and permanent outcome.

What, then, is the advantage of this unique method? Dr. Wu emphasizes that there is a triplanar correction. Correcting transverse plane alignment is but one important component. Restoration of the natural anatomical first metatarsal alignment concurrently provides for correction

## In spite of Dr. Wu’s success, the syndesmosis procedure remains largely ignored by the international foot surgery community.

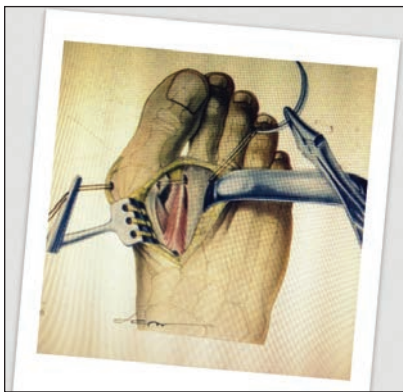

Figure 3: From Botteri & Castellana<sup>3</sup>

segmental anatomical weakness, one that leads to loss of soft tissue support to provoke the displacement of bony architecture away from natural anatomical alignment. The result is the progressive deformity of hallux valgus (Figure 4).

What specifically makes this approach unique? He alternates in his description, sometimes referring to the original descriptive term “osteodesis.”<sup>23</sup> At other times, he prefers the term syndesmosis, drawing on the analogous syndesmotic structure between fibula and tibia. He believes that both cerclage and the mini tight rope can effectively reduce what he considers the primary problem—metatarsus primus varus. But, he continues, what of maintenance? Those procedures rely on a synthetic mechanical

in the sagittal plane position and range of motion, in addition to the frontal plane position. The first metatarsal, in short, is re-positioned to where it should be naturally.

When the bone itself is not deformed, why would a surgeon choose to create a surgical deformity? It is entirely desirable and possible to fix the problem without the need to ‘break’ the bone, i.e., osteotomy, by cutting and shifting bone, or fusing a healthy joint, such as the Lapidus procedure. In fact, he emphasizes, the natural anatomy of the foot should be altered as little as possible to restore natural unimpaired function. “Less is more”, he reiterates—a recurring theme in the surgical philosophy of Dr. Wu.

With a series of x-rays, he discusses examples of the Lapidus, and of first metatarsal osteotomies. The

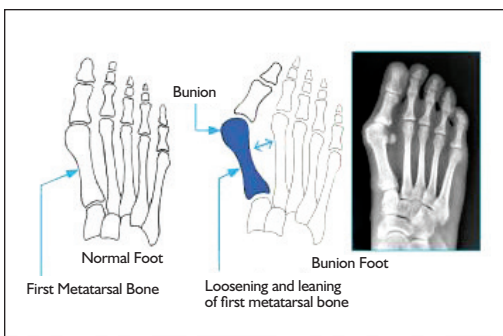
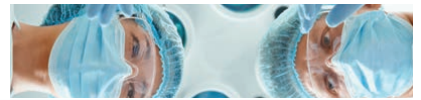


Figure 4: Courtesy of Dr. Wu

*Continued on page 119*



## Syndesmosis Procedure (from page 118)

outcome looks good, on the face of it but, he says, look more closely. The sesamoid position can look good, but look at the gap between the first and second metatarsal heads after the operation. When you compare the outcome with the syndesmosis, there is indeed a significant difference.

In the operating room, Dr. Wu demonstrates his mastery of the technique. (Figure 1) He describes, in his operative report, a 3.0cm dorsal incision, but the actual incision is barely 2.0cm, or less. "That's all that is required," says Wu. There is good access to all the essential structures. The beginner surgeon may prefer a slightly longer incision, he adds. (Figure 5) He continues with the surgery in a precise and careful fashion.

Every maneuver is deliberate and has purpose. He takes time to demonstrate carefully the anatomy as it is encountered. Pointing with a curved hemostat, used for blunt dissection, he draws attention to the exposed medial branch of the deep peroneal nerve. This is retracted. "We don't want to injure this," he explains. The deep fascia is incised, exposing the interosseous muscle. From his surgical observation, this muscle is frequently hypertrophied.

When necessary, the dorsal third is excised. There has been no loss of stability or alignment from this maneuver. Bleeding from cut muscle

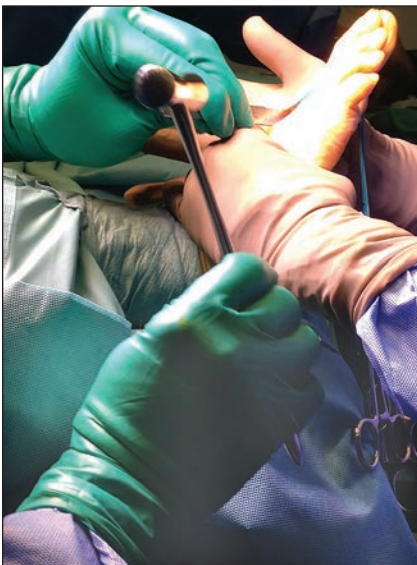


Figure 6: Feathering

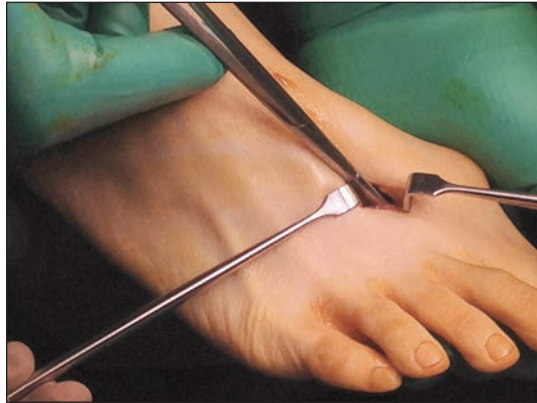

Figure 5: Incision

also does not appear to be a cause for concern. Next, attention is directed to the second metatarsal shaft which is exposed. When this is completed, the

release adequately, but just enough, and without the risk of overcorrection, the iatrogenic hallux varus. Only the fibular sesamoid suspensory and lateral collateral ligament is freed. Any subsequent release is carefully evaluated and may be adjusted to the severity of the contracture. Next, the periosteum is stripped from the shaft of the first metatarsal, with just enough exposure. Next, using a 2.0mm drill, 2-4 holes are placed in the shaft of the first metatarsal.

The surgical scene is set for the preparation of bone that is at the

## Restoration of the natural anatomical first metatarsal alignment concurrently provides for correction in the sagittal plane position and range of motion, in addition to the frontal plane position.

focus is the lateral release of the first metatarsal phalangeal joint.

This is performed judiciously. MPV (metatarsus primus varus) correction is powerful, he emphasizes, and the primary concern now is to

heart of the syndesmosis. Using a 12 mm osteotome and small mallet (19cm, 230 gram), the bone is elevated by fish scaling, with a series of deftly controlled strikes. Normal bone physiology takes over from here, adds Dr. Wu, who admits he does not know exactly what happens after that. The new tissue that forms has never been investigated histologically. He is hopeful that, one day, an academic institution will rise to the challenge, to answer that question. (Figure 6)

He inspects the interspace. Fat is the enemy. Any fatty tissue must be removed as this interferes with the anticipated biological response. After this is completed, he feeds the suture through the prepared holes and encircles the second metatarsal. Applying firm pressure, the intermetatarsal angle is reduced manually, and two throws of suture are secured temporarily with a hemostat.

The result is checked by x-ray,

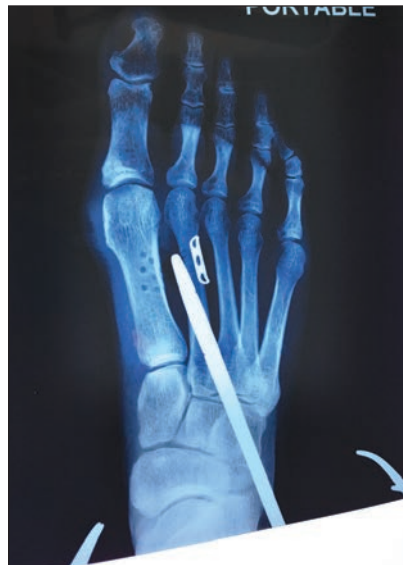

Figure 7: Intra-Op XR

*Continued on page 122*



## *Syndesmosis Procedure (from page 119)*

and the position is found to be satisfactory (Figure 7). Another recent technical adjustment is the application of the 4-hole AO mini-plate, applied to the lateral cortex of the second metatarsal shaft. The incidence of second metatarsal fractures is low, and he hopes to further control the outcome in this way. The temporary suture is completed, and additional sutures are added, as necessary. Pointing at the foot, he asks what I can see. I note the first metatarsal is moved into a more plantar position, following the surgical maneuver.

Next, the interspace is filled with platelet-rich fibrin (PRF) retrieved from the patient's own blood. This is introduced to promote and accelerate the desired biological bridge-forming fibrous response. It is as yet unknown what effect, if any, this might have. Two years ago, platelet-rich plasma was used, but abandoned when this failed to produce any discernible difference. He learned about this from a friend, a dental surgeon. After researching the material properties, he decided that this can perhaps provide a favorable substrate to optimize, perhaps accelerate, the fibrous bridge formation.

## **The ability of the syndesmosis to effectively and permanently correct MPV is undeniable.**

With all the key surgical elements in place, the wound is closed in the standard manner. When asked if he also uses a standard bunionectomy, he replies that this depends on the patient. When there is a significant exostosis, this is remodeled through a standard medial incision—often unnecessary, because the reduction is very powerful, especially in the young patient. But the older, more mature, and more severe bunion may deserve this additional attention. At the completion of the operation, a light dressing is applied. There is hardly any bleeding at all.

The ability of the syndesmosis

to effectively and permanently correct MPV is undeniable. The patient appears fully functional, happy with the outcome, and free of restriction in activity or footwear. Many patients elect to have bilateral correction. Dr. Wu is committed to long-term follow-up. There is no additional charge to his patients. The office pays the cab fare to encourage patients to re-

turn. Long-term follow-up can be problematic in Hong Kong where city people are busy. When the foot is no longer a concern, it can be difficult to entice a return visit.

Initial evaluation and follow-up are very thorough. Pre-op and post-operative evaluation incorporate clinical evaluation, standing radiographs, photographic evidence, and functional F-scan evaluation.

Especially noteworthy are the following observations:

1) First ray excursion range is measured and recorded. Sagittal

plane function consistently is controlled. On average, there is a 50% increase in first metatarsal stiffness. The patient population commonly demonstrates, pre-operatively, reduced first metatarsal stiffness (the hypermobile first ray). The fibrous tissue appears effective in promoting increased first metatarsal stiffness.

2) Clinical evaluation consistently demonstrates excellent and unrestricted first metatarsal phalangeal joint range of motion. 80-90 degrees represents the norm and not the exception. The quality of joint motion has a very natural feel.

3) Functional F-scan evaluation consistently demonstrates a restoration and medialization of weight-bearing pressures, together with restoration of hallux weight-bearing function and purchase, as compared to the pre-operative finding.

4) X-ray evaluation demonstrates excellent maintenance of MPV cor-

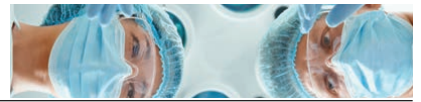
rection. Dr. Wu monitors this position extremely carefully after the surgery, with a passion bordering on obsession. Any indication of widening is followed up aggressively by adjusting the treatment protocol.

5) A particular surprise is the secondary stabilizing effect of the anatomically correct first metatarsal position. Lesser metatarsalgia is consistently eliminated, plantar forefoot callus vanishes or is significantly ameliorated, and flexible lesser toe deformity is reduced. Two of the patients concurrently had a problematic cross-over second toe. Only a medial release of the contracture, performed using the primary incision, was required. If the joint is dislocated, a percutaneous K-wire is used for four weeks.

## **Conclusion**

Our clinical judgment is a product of those principles passed on to us from our mentors during our training. New ideas dismissed by colleagues are sometimes misunderstood or simply ignored for 'daring to challenge' the dictum of the "gold standard". On occasion there is that peculiar individual who will not settle for the accepted 'standard of care' and dares to question the validity of our choices. A doctor such as that may all too easily be labelled a maverick zealot. The syndesmosis procedure, in the eyes of some, may fall into that category. It takes a firm conviction, nurtured by a lifetime of

*Continued on page 124*



## *Syndesmosis Procedure (from page 122)*

experience and successful outcome, to remain steadfast.

The surgical outcome is not 'bullet proof'. There is not a single surgical remedy capable of meeting such a lofty expectation. Complications can,

and do, occur. Managing the complication, more often managing the patient, is a familiar integral part of the art of medicine and surgery.

The syndesmosis is a technique that deserves to be better known.<sup>6</sup> This requires a more intense effort, in-depth scientific study, and par-

ticipation by a greater number of foot surgeons to form a collaborative international effort. Like Hong Kong itself, the syndesmosis technique is full of Eastern promise. And, as often as not, the experience meets the expectation. **PM**

## **Acknowledgments**

Dr. Eric Walter, DPM Residency Director, Montefiore Medical Center, Bronx, NY for facilitating the Hong Kong trip

Dr. Daniel Wu, MD Hong Kong, China for his guidance and mentorship.

## **References**

<sup>1</sup> [http://en.wikiquote.org/wiki/John\\_Maynard](http://en.wikiquote.org/wiki/John_Maynard), n.d.

<sup>2</sup> Cape, L. R. I. J., 1999. Intermetatarsal osteodesis: a fresh approach to hallux valgus. *The Foot*, Volume 9, pp. 93-98.

<sup>3</sup> Botteri G, Castellana A., 1961. L'osteodesi distale dei due primi metatarsi nella cura dell' alluce valgo. *La Clinica Ortopedica*, XIII(Fasc 1), pp. 39-46.

<sup>4</sup> Daniel Yiang Wu, 2007. Syndesmosis Procedure: A Non-Osteotomy Approach to Metatarsus Primus Varus Correction. *FOOT & ANKLE INTERNATIONAL*, 9, pp. Vol. 28, No. 9, pp 1000-6.

<sup>5</sup> Wu D, 2006. A Non Osteotomy Technique for Hallux Valgus Correction. *Hong Kong J Ortho Surg*, 10(1), pp. 34-38.

<sup>6</sup> Pagella P, Pierleoni. G., 1971. Hallux Valgus and Its Correction. A Technique That Deserves To Be Better Known *Istituto Ortopedico Toscano*, 1(55).

<sup>7</sup> Wong DW, W. D. M. H. L. A., 2014. The use of a syndesmosis procedure for the treatment of hallux valgus: good clinical and radiological results two years post-operatively. *Bone Joint J.*, Volume 96-B(4), pp. 502-7.

<sup>8</sup> Wu DY, L. K., 2014. Osteodesis for Hallux Valgus Correction: Is it Effective?. *Clin Orthop Relat Research*, p. October 28.

<sup>9</sup> Wu D, Lobo L, 2010 Does Wearing High Heeled Shoes Cause Hallux Valgus? A Survey of 1,056 Chinese Females, *Foot & Ankle Online Journal* 3: (5): 3.



## **Dieter J. Fellner**

worked in the National Health Service, England as a Consultant Podiatric Surgeon. In 2013, he graduated from the New York College of Podiatric Medicine and is currently completing a three-year surgical

residency at Montefiore Medical Center, Bronx, New York.